

Real-time Semi-automatic Segmentation of Hepatic Radiofrequency Ablated Lesions in an *In Vivo* Porcine Model Using Sonoelastography

B. Castaneda, M. Zhang, K. Hoyt, K. Bylund, J. Christensen, W. Saad, J. Strang, D.J. Rubens, and K.J. Parker
Rochester Center for Biomedical Ultrasound
University of Rochester
Rochester, NY, USA

Abstract— Radiofrequency ablation (RFA) is a minimally invasive thermal therapy that is under investigation as an alternative to surgery for treating liver tumors. Currently, there is a need to monitor the process of lesion creation to guarantee complete treatment of the diseased tissue. In a previous study, sonoelastography was used to detect and measure RFA lesions during exposed liver experiments in a porcine model *in vivo*. Manual outlining of these lesions in the sonoelastographic images is challenging due to a lack of boundary definition and artifacts formed by respiratory motion and perfusion. As a result, measuring the lesions becomes a time-consuming process with high variability. This work introduces a semi-automatic segmentation algorithm for sonoelastographic data based on level set methods. This algorithm aims to reduce the variability and processing time involved in manual segmentation while maintaining comparable results. For this purpose, eleven RFA lesions are created in five porcine livers exposed through a midline incision. Three independent observers perform manual and semi-automatic measurements on the *in vivo* sonoelastographic images. These results are compared to measurements from gross pathology. In addition, we assess the feasibility of performing sonoelastographic measurements transcutaneously. The procedure previously described is repeated with three more lesions without exposing the liver. Overall, the semi-automatic algorithm outperforms manual segmentation in accuracy, speed, and repeatability. These results suggest that sonoelastography in combination with the segmentation algorithm has the potential to be used as a complementary technique to conventional ultrasound for thermal ablation monitoring and follow-up imaging.

Keywords—Radiofrequency ablation; sonoelastography; semi-automatic segmentation

I. INTRODUCTION

Thermal ablation techniques such as radiofrequency ablation (RFA) and high intensity focused ultrasound have attracted the interest of the research community for their minimally invasive approach to treating tumors [1,2]. In particular, promising results have been reported in early clinical trials for the treatment of hepatic tumors [3,4]. Imaging modalities that dynamically and precisely monitor the lesion during and after treatment are crucial for the success of RFA therapies.

Ultrasound (US) is generally used for imaging guidance during ablation procedures. It offers convenient real-time guidance of RFA needle placement and it is available on most clinical sites. However, it fails to monitor the creation of RFA lesions accurately [3]. Besides the low intrinsic echogenic contrast between treated and untreated tissues, artifacts due to gas bubbles created during the RFA process appear as hyperechoic formations and seriously compromise B-scan imaging [5]. This cluster of gas bubbles does not represent accurately the extent of ablation. The bubbles resolve gradually, resulting in underestimation of the lesion size. On the other hand, magnetic resonance imaging capabilities on resolving soft tissues can be used to discriminate thermally ablated from healthy tissue [6], but the procedure becomes expensive and time consuming. Computed Tomography (CT) in combination with contrast agents has also been proposed [7]. In this modality, thermally ablated lesions are depicted as hypo-attenuating regions. However, it also presents disadvantages such as exposure to ionizing radiation, side effects of CT contrast agents, and extended time of the procedure.

Thermally ablated lesions present an elevated elasticity modulus when compared to the surrounding tissue [8]. Consequently, elasticity imaging modalities have been proposed as an alternative to monitoring lesion creation and follow-up imaging [9]. In particular, sonoelastography [10] is an imaging technique that estimates the peak displacement of tissue under an externally induced mechanical harmonic excitation [11]. In a previous study, sonoelastography was used to detect and measure RFA lesions *in vivo* in exposed liver experiments [5]. Manual measurement of these lesions in the sonoelastographic images is challenging due to a lack of boundary definition and artifacts formed by respiratory motion and perfusion. As a result, outlining and measuring the RFA lesions becomes a time-consuming process with high variability.

In this paper, we evaluate the performance of a semi-automatic segmentation algorithm in measuring RFA lesions in a porcine liver model *in vivo*. The first set of experiments was performed using an exposed liver setup, while the second set was done transcutaneously in order to simulate real clinical conditions.

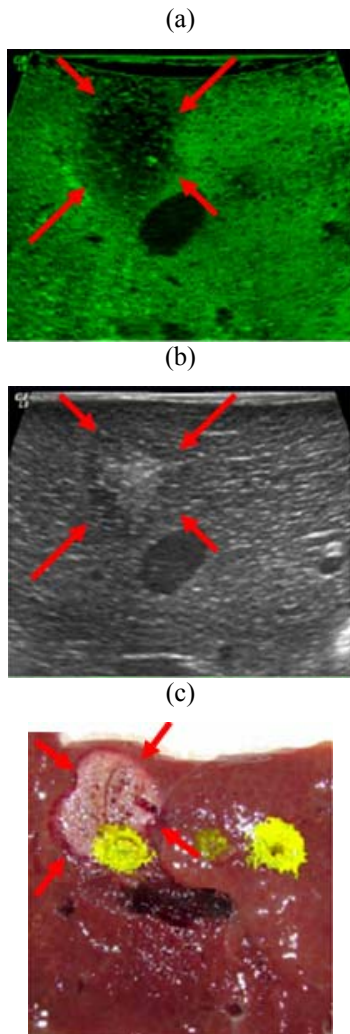


Figure 1. Matched (a) sonoelastographic, (b) US B-mode, and (c) Gross pathology images. The red arrows show the RFA lesion next to a vessel. Note that the hyperechoic region in the B-mode image does not cover the whole area of the lesion.

II. MATERIALS AND METHODS

A. Exposed liver experiments

Eleven RFA lesions were created in five porcine livers. In each case, the pig was anesthetized and prepared for surgery. Subsequently, its abdomen was shaved and a laparotomy was performed along the ventral midline and subcostal area to expose the liver. This procedure was performed by the professionals at the Division of Laboratory Animal Medicine (DLAM) following the animal use protocol approved by the University Committee on Animal Resources (UCAR) at the University of Rochester.

An RFA needle (LeVeen needle electrode, Boston Scientific, Natick, MA, USA) was inserted in the liver under US B-mode guidance. The needle was connected to an RF generator (RF 3000 Radiofrequency Ablation System, Boston Scientific, Natick, MA, USA). Following an established treatment algorithm for clinical practice [8], an RFA lesion was created 1–2 cm beneath the liver surface. Two pistons (Model

2706, Brüel & Kjaer, Naerum, Denmark) were applied directly on the surface of the liver to generate the vibration field needed for sonoelastography. Input signals to the vibration sources were produced by a harmonic waveform generator (Model 3511A Pragmatic Instruments, San Diego, CA, USA) after amplification (Model 2706, Brüel & Kjaer, Naerum, Denmark). The pistons were vibrated at a combination of low frequencies (105, 140, 175 and 210 Hz). Co-registered sonoelastographic and B-mode images were acquired using a linear probe array (M12L) connected to a Logiq 9 US scanner (General Electric Medical Systems, Milwaukee, WI, USA). The position and orientation of the probe over the liver was marked. After imaging, the pig was euthanized and the liver was excised. For each lesion, gross pathology was obtained approximately at the same position and orientation in which it was imaged. Subsequently, gross pathology was photographed and considered to be ground truth.

Three independent observers measured the area of each of the lesions from the sonoelastographic images using manual segmentation. One observer repeated this procedure three times with a week span in between measurements. The same three observers repeated the process utilizing a semi-automatic segmentation algorithm. The algorithm requires an initialization step in which the user selects the center of the lesion. Given this input, a region growing technique based on watershed segmentation is first applied to define an estimate of the area of the lesion. Subsequently, level-set methods are used to refine the shape of the lesion. Similarly to manual segmentation, one observer measured the lesions three times with the semi-automatic algorithm. From all measurements, interobserver and intraobserver variabilities were assessed for manual and semi-automatic segmentation. In all cases, the time to perform the segmentation was recorded and the area of the lesions was compared to gross pathology.

B. Transcutaneous experiments

Three RFA lesions were created and measured transcutaneously in two porcine livers. The protocol followed was similar to that detailed in Section IIA, except that the lesions were created and imaged without exposing the liver. The vibration sources were applied on the abdomen, just touching the skin. A 3.5 MHz curvilinear probe (3.5C) was used for imaging. Subsequently, the animal was euthanized and the liver was excised. The procedure for measuring the lesions was the same as described previously.

III. RESULTS

In the exposed liver experiments, eleven RFA lesions were created in five pigs. The imaged area of the lesions ranged from 26.4 mm² to 237.1 mm². Three more lesions were created and imaged transcutaneously. Their area ranged from 365 mm² to 375 mm². Table 1 summarizes the results for the experiments in terms of accuracy, repeatability and time of segmentation. Results showed that the semi-automatic algorithm outperforms manual segmentation in all aspects evaluated. In particular, the time to measure a lesion reduces significantly from 4 minutes to 12 seconds. Segmentations in lesions created and imaged transcutaneously showed decreased accuracy and higher variability.

TABLE I. COMPARISON BETWEEN MANUAL AND SEMI-AUTOMATIC METHODS FOR RFA LESION SEGMENTATION

	Number of lesions	Correlation coefficient (%)	Average error (mm ²)	Max error (mm ²)	Intra-observer coefficient of variation (%)	Inter-observer coefficient of variation (%)	Average segmentation time per lesion (min)
Exposed Liver							
Manual segmentation	11	84.6	25.7	87.4	1.8	5.3	3.9
Algorithm	11	96.5	12.3	33.2	0.4	0.9	0.2
Transcutaneously							
Manual segmentation	3	-	128	321	3.2	9.0	3.8
Algorithm	3	-	25.7	52.7	0.4	2.6	0.2

Matched sonoelastographic, B-mode and gross pathology images are presented in Fig. 1. An RFA lesion is found at the top left of the sonoelastographic image next to a vessel. The corresponding B-mode image shows a hyperechoic region due to the gas bubbles formed by the RFA process. The area of the hyperechoic regions does not correspond to the area of the actual lesion. The gross pathology image confirms the presence of the lesion next to a vessel which has collapsed after the liver was excised.

A comparison between manual and semi-automatic segmentation is illustrated in Fig. 2. Three independent observers manually drew different outlines for the same lesion. The same observers initialized the semi-automatic algorithm by picking the center of the lesion. Even though they picked different centers, the algorithm produced the same outline.

Fig.3 depicts an example of a sonoelastographic image obtained transcutaneously and the outline of the lesion generated by the semi-automatic algorithm. In general, these images presented a lower signal-to-noise ratio (SNR) when compared to exposed liver results.

IV. DISCUSSION

Results show that sonoelastography can be used to measure RFA lesions. However manual segmentation of the lesions presents challenges in terms of variability and processing time required. These problems make manual segmentation unfeasible for real-time monitoring of the ablation procedure.

The semi-automatic algorithm presented in this work improves the overall performance of sonoelastography in terms of accuracy and repeatability. In addition, the time to measure the lesion was considerably reduced to less than 15 seconds. Therefore, real time measurements (and monitoring) of the lesions are possible. In this context, the algorithm needs to be initialized only at the beginning of the treatment. Subsequently, the resulting outline can be used as the input for the segmentation of the lesion in the following image during the length of the procedure.

Results from the transcutaneous experiment indicate that accuracy and repeatability decrease when compared to exposed

liver experiments. This was expected since coupling the vibration sources transcutaneously lowered the SNR of the image. Therefore, there is a need to find more efficient ways to transmit mechanical vibrations to the tissue whereby improving sonoelastographic image quality.

V. CONCLUSION

A semi-automatic algorithm to segment deficits from sonoelastographic images is presented and applied to measure RFA lesions. These lesions were created and imaged in a porcine liver *in vivo*. One set of experiments was performed exposing the liver and applying the vibration sources to its surface. Another set was performed transcutaneously to simulate a real clinical setting. Sonoelastographic results showed good correlation with pathological data. Measurement of lesions created and imaged transcutaneously shows decreased accuracy and higher variability due to the lower signal to noise ratio of the images. Overall, the semi-automatic algorithm outperforms manual segmentation in terms of accuracy, repeatability and speed. These results suggest that sonoelastography in combination with the segmentation algorithm has the potential to be used as a complementary technique to conventional ultrasound for thermal ablation monitoring and follow-up imaging.

ACKNOWLEDGMENT

The authors would like to thank Vikram Dogra, Malcolm Bean, Amy Lerner, Art Salo, Peng Wang, Sally Child and Carol Raeman for their suggestions and help. This research was sponsored by the Fischer Fund Grant 4-50275 and by NIH Grant 5 R01 AG016317-06.

REFERENCES

- [1] J.T. De Sanctis, S.N. Goldberg, and P.R. Mueller, "Percutaneous treatment of hepatic neoplasms: A review of current techniques," *Cardiovasc. Intervent. Radiol.*, vol. 21, pp. 273–296, 1998.
- [2] S.N. Goldberg, G.S. Gazelle, and P.R. Mueller, "Thermal ablation therapy for focal malignancy: A unified approach to underlying

principles, techniques, and diagnostic imaging guidance,” *AJR. Am. J. Roentgenol.*, vol. 174, pp.323–331, 2000.

- [3] L. Solbiati, T. Ierace, S.N. Goldberg, S. Sironi, T. Livraghi, R. Fiocca, et al., “Percutaneous US-guided radio-frequency tissue ablation of liver metastases: Treatment and follow-up in 16 patients,” *Radiol.*, vol. 202, pp. 195-203, 1997.
- [4] L. Solbiati, S.N. Goldberg, T. Ierace, T. Livraghi, F. Meloni, M. Dellanoce, et al., “Hepatic metastases: Percutaneous radio-frequency ablation with cooled-tip electrodes,” *Radiol.*, vol. 205, pp. 367-373, 1997.
- [5] M. Zhang, “The measurement and imaging of viscoelastic properties of soft tissues and lesions,” Ph.D. Dissertation, University of Rochester, 2007.
- [6] J. Hindley, W.M. Gedroyc, L. Regan, E. Stewart, C. Tempny, K. Hynnen, et al., “MRI guidance of focused ultrasound therapy of uterine fibroids: Early results,” *AJR. Am. J. Roentgenol.*, vol. 183, pp. 1713-1719, 2004.

- [7] C.H. Cha, F.T. Lee, J.M. Gurney, B.K. Markhardt, T.F. Warner, F. Kelcz, et al., “CT versus sonography for monitoring radiofrequency ablation in a porcine liver,” *AJR. Am. J. Roentgenol.*, vol. 175, pp. 705-711, 2000.
- [8] S.A. Curley, “Radiofrequency ablation of malignant liver tumors,” *Oncologist*, vol. 6, pp. 14-23, 2001.
- [9] T. Varghese, U. Techavipoo, W. Liu, J.A. Zagzebski, Q. Chen, G. Frank, and F.T. Lee Jr., “Elastographic measurement of the area and volume of thermal lesions resulting from radiofrequency ablation: Pathologic correlation,” *AJR. Am. J. Roentgenol.*; vol. 181, pp. 701-707, 2003.
- [10] R.M. Lerner, K.J. Parker, J. Holen, R. Gramiak, and R.C. Waag, “Sonoelasticity: Medical elasticity images derived from ultrasound signals in mechanically vibrated targets,” *Acoust. Imaging*, vol. 16, pp. 317-327, 1988.
- [11] S.R. Huang, R.M. Lerner and K.J. Parker. “On estimating the amplitude of harmonic vibration from the Doppler spectrum of reflected signals,” *J. Acoust. Soc. Am.*, vol. 88, pp. 310-317, 1990.

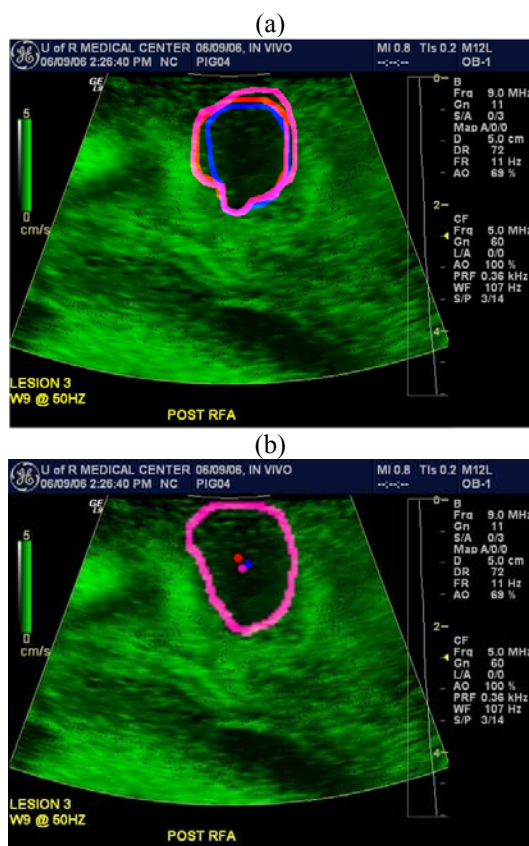


Figure 2. Comparison between (a) Manual and (b) Semi-automatic segmentation. Three independent observers (shown in blue, pink and violet) manually outlined the lesion and selected the center of the lesion to initialize the semi-automatic algorithm.

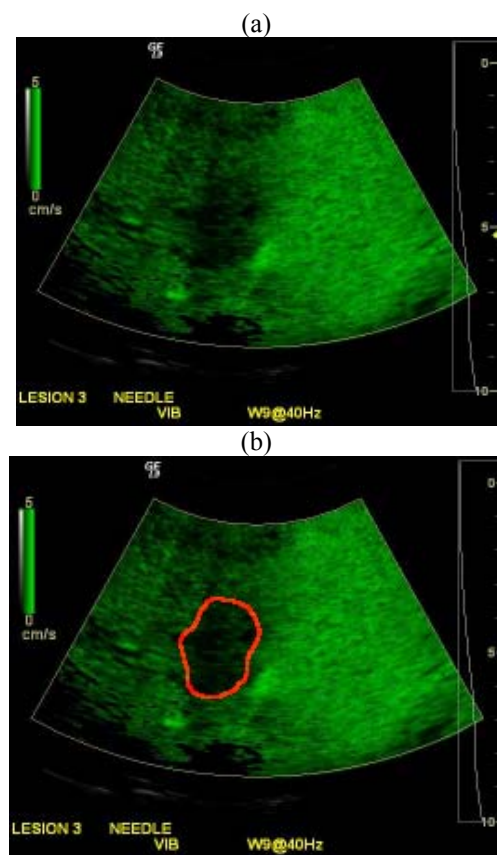


Figure 3. (a) Sonoelastographic image of an RFA lesion created transcutaneously and (b) Segmentation performed by the semi-automatic algorithm.